SonoPath
Clinical Sonography & Telecytology
EDUCATIONAL TELECONSULTATION SERVICES™
1-800-838-4268 info@sonopath.com SonoPath.com

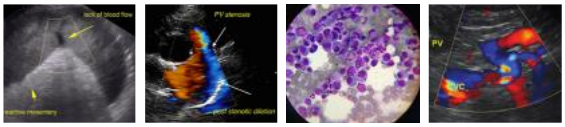

ANIMAL SOUNDS NW
MOBILE VETERINARY ULTRASOUND
IMAGING PERFORMED BY
AnimalSoundsNW.com 541-357-9423

PATIENT
Jingle Burrell

SPECIES
Feline

BREED
DLH

SEX
Female Spayed

AGE
18 years

WEIGHT
7.06lbs

INTERPRETED BY
Maggie Machen Lamy, DVM, DACVIM (Cardiology)

IMAGING PERFORMED BY
Sara Hansen

HOSPITAL NAME
Q Street Animal Hospital

REFERRING VET
Dr. Cone

INVOICE
28227

DATE
1/10/23

PRESENTING CLINICAL SIGNS

History: Recheck echo. History of hyperthyroidism. Recently started vomiting after drinking, wheezing, slight decrease in appetite and weight loss (1lb). BP: 140mmHg (2 months ago).
-Current medications: Methimazole, Atenolol, Miratax.
-Pertinent previous echo findings (6/2022 MML): Moderate LVH, mild LAE, severe LVOTO: 5m/s, moderate MR. LV: 0.73/0.71.

ELECTROCARDIOGRAPHIC FINDINGS *Note: Single lead ECGs are evaluated as a rhythm strip. Morphology/MEA cannot be definitively commented on.

A single lead ECG is available; 50mm/s, 20mm/mV. The average heart rate is 175bpm with a regular rhythm. The rhythm is sinus in origin, with a p for every QRS complex and vice versa. The P morphology is positive. The QRS is inverted. No ectopic beats, pauses or dysrhythmias observed.
ECG diagnosis: Normal sinus rhythm.

ECHOCARDIOGRAM FINDINGS

2D, m-mode, color flow and doppler imaging is available. The left ventricular wall is mildly hypertrophied with regions of irregularity. There is a diffusely hyperechoic endocardium consistent with fibrosis and ventricular remodeling. Papillary muscle hypertrophy. The right ventricle is subjectively normal in size and morphology. There is no left atrial enlargement present. No right atrial enlargement present. Normal RVOT velocity. There is systolic anterior motion (SAM) of the mitral valve is not apparent in this exam. There is trace eccentric mitral regurgitation. Trace TR. No other obvious valvular regurgitation is present. There is no pericardial effusion noted. No pleural effusion appreciated.

CARDIAC CHART

FELINE CARDIAC PARAMETERS	BODY WEIGHT (kg)	HR (BPM)	IVSd (cm) (Moise, Pipers)	LVIDd (cm) (Moise, Pipers)	LVWd (cm) (Moise, Pipers)	FS (%)	EF (%)
NORMAL PARAMETER	------	150-240	0.35-0.55	<2 (mean 1.5)	3.5-0.55	35-67	80-100
PATIENT	3.2	NM	0.63	1.3	0.60	58	92

FELINE CARDIAC PARAMETERS	LA/AO (Boon)	LA/AO HEART BASE (Swe) (Abbott)	LA 2D short axis Base view (cm) (Abbott)	LVOT VEL (m/s)	RVOT VEL (m/s)	E max (m/s)
NORMAL	<1.5	<1.3	<1.2	<1.6	<1.3	<0.9
PATIENT	NM	1.2	1.1	1.7	1.0	NM

Note: All measurements based upon multi-modal images and methods. An average value is reported.
Adapted from June Boon, Veterinary Echocardiography,1998
Abbott J & MacLean H JVIM 2006;20: 111-119, Moise et al. Am J Vet Res 47:1476, 1986. Pipers et al. Am J Vet Res 40:882, 1979.

INTERPRETATION OF THE FINDINGS & FURTHER RECOMMENDATIONS

Compared to the prior study, there is evidence of improvement. Previously moderate LVH is now mild with a normalized LA dimension. The LVOTO is not apparent, likely due to Atenolol therapy. No additional issues are identified and the ECG is unremarkable.

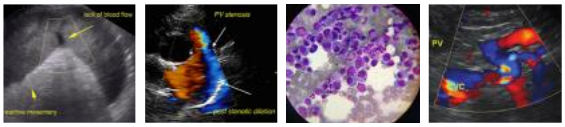

PATIENT
Jingle Burrell

SPECIES
Feline

BREED
DLH

SEX
Female Spayed

AGE
18 years

WEIGHT
7.06lbs

INTERPRETED BY
Maggie Machen Lamy, DVM, DACVIM (Cardiology)

IMAGING PERFORMED BY
Sara Hansen

HOSPITAL NAME
Q Street Animal Hospital

REFERRING VET
Dr. Cone

INVOICE
28227

DATE
1/10/23

Given these findings, certainly continue Atenolol therapy lifelong as the improvement here is significant.

Prognosis remains guarded; however, this is certainly encouraging.

Anesthetic risk is considered mild, however judicious IV fluid rates are advised to avoid fluid overload. Additionally, drugs that stimulate heart rate should be avoided unless clinically necessary (glycopyrrolate, atropine). Avoid vasodilators as this may worsen the obstruction. A reasonable protocol includes opioid/benzodiazepine premedication, propofol induction, isoflurane maintenance. Risk for complication with steroid use typically follows LA dilation, which in this case is mildly elevated. If needed, monitoring of RR/RE is advised particularly in the initiation phase.

Monitor at home for any respiratory signs or blood clot events (neurologic change, paralysis, etc.) in the future.

PLAN

Screening BP/T4 every 6 months. Continue Atenolol as prescribed.

Recommend recheck echocardiogram in 6 months to assess for progression, sooner if clinical issues arise.

IMAGES

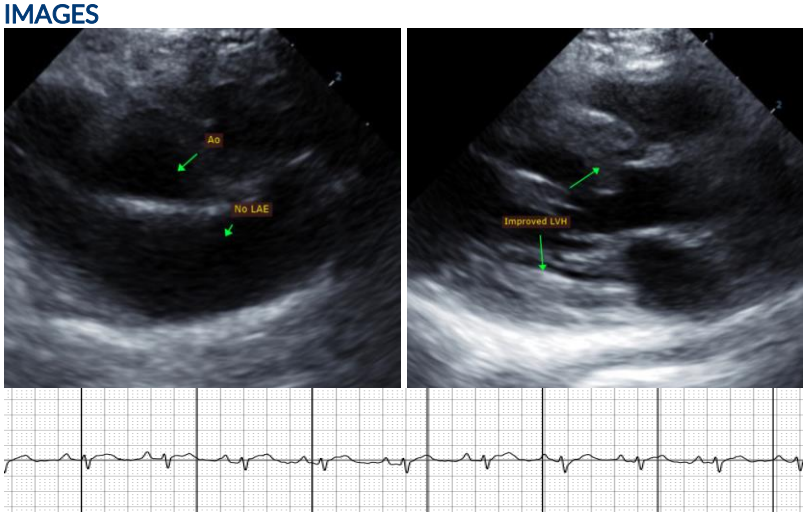

The information and recommendations provided are based on the images presented by the referring veterinarian. No evaluation can be communicated regarding pathology that was not visible in the image/video clips provided.

Thank you for this referral. This report was generated using transcription software, and minor dictation errors may be present. If the clinical or image interpretation does not parallel your findings or if I can be of any further assistance, please contact me.

Maggie Machen Lamy, DVM
Diplomate of the American College of Veterinary Internal Medicine (Cardiology)
info@sonopath.com